

## Hair and cutaneous phenotypes linked to Arrhythmogenic Cardiomyopathy caused by Desmoplakin haploinsufficiency: an additional disease marker

S. Castelletti<sup>1</sup>, T. Maruthappu<sup>2</sup>, A. Posafalvi<sup>2</sup>, P. Syrris<sup>3</sup>, E.A. O'Toole<sup>2</sup>, K.J. Green<sup>1</sup>, A. Tinker<sup>2</sup>, W.J. McKenna<sup>3</sup>, D.P. Kelsell<sup>2</sup>.

<sup>1</sup>Italian Institute for Auxology IRCCS, Milan, Italy; <sup>2</sup>Queen Mary University of London, London, United Kingdom; <sup>3</sup>University College London, London, United Kingdom;

5 major desmosomal genes account for 40–60% of cases, being Desmoplakin (DSP) mutations responsible for 2–12% of them. Desmosomes represent the major cell-cell structures. They contribute to the myocardial electromechanical adhesion complex and to the skin mechanoresilience. AC early diagnosis is still challenging due to the highly variable phenotypic expression and incomplete penetrance. Rare recessive AC DSP forms can be associated with woolly hair and palmoplantar keratoderma, whilst traditionally autosomal dominant forms are considered to be cardiac specific without involvement of skin and hair. **Purpose:** To assess skin and hair involvement in heterozygous mutation DSP carriers.

**Methods:** 5 Caucasian AC families with 32 carriers of a dominant truncation or frameshift mutation in DSP were included in the study. Patients were diagnosed with AC according to the revised Task Force Criteria. Deep hair and skin clinical phenotyping was carried out by a dermatologist. Punch biopsy of nonlesional skin was performed in 8 patients for molecular characterization.

**Results:** All 32 mutations carriers had curly/wavy hair, 5.8 times the incidence observed in the general population. None of the non-mutation carriers members had curly/wavy hair. Some patients also showed a palmoplantar keratoderma with hyperkeratosis and fissuring at pressure-bearing sites (Fig. 1B). Sanger sequencing of nonlesional skin cDNA suggested degradation of the mutant allele at the mRNA level (Fig. 1A). Immunohistochemical staining also revealed dysregulation of Dsp. An abnormal expression pattern was observed also for Plakoglobin and Connexin43 (Fig. 1C and Fig 1D).

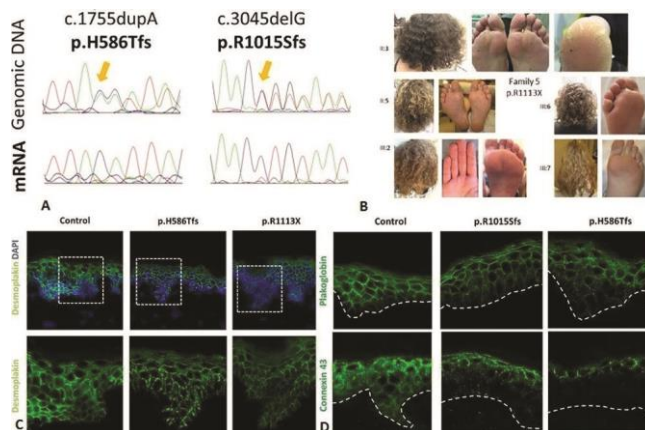


Figure 1

**Conclusions:** Heterozygous truncating DSP mutations in AC cause abnormal localisation of desmosomal proteins and connexin 43 in the skin, leading to a form of cardiocutaneous syndrome. This additional cutaneous clue may help the differential and timely diagnosis of AC in patients with arrhythmias and/or family history of sudden death, or even in the absence of overt cardiac disease features.

**Funding Acknowledgements:** ESC Research grant